

# Desquamative interstitial pneumonia: A case report

HAILONG ZHANG<sup>1</sup>, GUOHUA YU<sup>2</sup>, BEN YANG<sup>1</sup>, SHENGYAO MA<sup>2</sup>,  
YUBING WANG<sup>1</sup>, XIAOQI ZHANG<sup>2</sup>, YONG ZHANG<sup>2</sup> and MEI-HUA QU<sup>1,2</sup>

<sup>1</sup>Biopharmaceutical Laboratory, Key Laboratory of Shandong Province Colleges and Universities,  
School of Life Science and Technology, Weifang Medical University, Weifang, Shandong 261053;

<sup>2</sup>Department of Respiratory and Critical Care Medicine, Translational Medical Center,  
Weifang Second People's Hospital, Weifang Respiratory Disease Hospital, Weifang, Shandong 261041, P.R. China

Received August 10, 2023; Accepted December 18, 2023

DOI: 10.3892/etm.2024.12487

**Abstract.** Diffuse cystic lung diseases (DCLDs) are a group of heterogeneous lung diseases that are characterized by inflated spaces or cysts within the lung parenchyma. They also exhibit similar imaging characteristics and clinical manifestations compared with those of cystic lesions, such as pulmonary cavities, emphysema, bronchiectasis and honeycomb lung. The most common DCLDs encountered in the clinic include lymphangioleiomyomatosis, Birt-Hogg-Dubé syndrome, Langerhans cell histiocytosis and lymphocytic interstitial pneumonia. In particular, accurate diagnosis of DCLDs in terms of the different lesions found is important, because their clinical courses, prognoses and treatment strategies vary widely. However, because DCLDs usually have overlapping clinical presentations, diagnosis typically requires a combination of clinical considerations that take into account characteristics of the cyst, its distribution, organ of origin and background parenchymal findings. The present report documents the case of a 73-year-old man diagnosed with desquamative interstitial pneumonia (DIP). The patient was admitted to the hospital due to chest tightness, shortness of breath and intermittent fever. The patient had been a smoker for >60 years and had stopped smoking for 6 months before being admitted. A transbronchial lung biopsy, bronchoscopy and alveolar lavage cytopathogen culture were performed to confirm the diagnosis of desquamative interstitial pneumonia (DIP). The patient was treated with hormonal therapy and advised to abstain from smoking. The diagnosis of DIP in comparison with other DCLDs was summarized for the purpose of providing a clinical basis for

the accurate clinical diagnosis of DIP and the development of evidence-based practice guidelines.

## Introduction

Pulmonary cystic disease is a circular, thin-walled, well-defined attenuation area in the lung parenchyma (1). The wall thickness is <2 mm and the space is usually filled with gas or liquid (2). The cystic wall is typically comprised of epithelial cells or fibrous tissue, which needs to be differentiated from cystic diseases, such as emphysema, bullae, cavitory disease and honeycomb lung (3). Diffuse cystic lung diseases (DCLDs) occur when there are multiple cystic lesions in the lung parenchyma caused by different diseases (4), including *Yersinia* lung, *Staphylococcal* pneumonia, lung Langerhans histiocytosis, lymphangioleiomyomatosis, lymphocytic interstitial pneumonia (LIP) and Birt-Hogg-Dubé (BHD) syndrome. Different DCLDs have similar clinical manifestations, but the treatment and intervention methods after diagnosis are somewhat different (5). Therefore, delineating the diagnosis and identifying the causes of different DCLDs are essential for selecting the subsequent treatment strategy.

Desquamative interstitial pneumonia (DIP) is a rare form of interstitial lung disease. This disease was first defined and named by Liebow and Billingsley (6) in 1965 and was proposed to exhibit various features, such as alveolar infiltrates derived from alveolar epithelial cell desquamations, relatively slight alveolar thickening, monotonous homogeneity of the lesions and a typical but non-specific ground glass appearance of the lung margins. However, subsequent studies have shown that the infiltrates represent not desquamation but instead pigmented macrophages (7,8). DIP is commonly associated with smoking-related lung disease. Previous studies have shown that about 90% or more of patients had a history of smoking. However, close to 10% of the population still develops DIP due to systemic diseases, infections, environmental/occupational exposure to hazardous substances, and medications (9,10). Therefore, the association between smoking and DIP is not as robust as that with several other smoking-related lung diseases. For example, 100% patients with interstitial lung disease associated with respiratory bronchitis have been documented to be smokers (11). This suggests that other factors, such as

---

*Correspondence to:* Professor Mei-Hua Qu, Biopharmaceutical Laboratory, Key Laboratory of Shandong Province Colleges and Universities, School of Life Science and Technology, Weifang Medical University, 7166 Baotong West Street, Weifang, Shandong 261053, P.R. China  
E-mail: qumeihua@hotmail.com

**Key words:** diffuse cystic lung disease, disease diagnosis, desquamative interstitial pneumonia

systemic diseases, infections, environmental or occupational exposure to harmful substances and medications, may also be associated with DIP.

In terms of clinical diagnosis, desquamative interstitial pneumonia (DIP) shares many features with other diffuse cystic lung diseases (DCLDs) such as lymphangioleiomyomatosis (LAM) and pulmonary Langerhans cell histiocytosis (PLCH). It is necessary to review the diagnosis of the different DCLDs (10). DIP is characterized by the accumulation of pigmented macrophages in the distal airways and spaces (7). Specific manifestations of LAM include cystic changes and LAM cytolysis, while chest CT manifestations of PLCH usually include a combination of nodules and cysts. Nodules are typically 1-10 mm in size and are generally located in the small bronchi (4). Furthermore, alveolar filling tends to be more diffuse and homogeneous in DIP, which is frequently accompanied with inflammatory cell-induced septal thickening, mild interstitial fibrosis and/or centrilobular emphysema (3). At present, the diagnosis of DIP mainly relies on CT and biopsy. Other pathological or laboratory tests are only sufficient to serve as auxiliary but non-specific indicators (3). Treatment for DIP mainly entails glucocorticoid therapy, though there is currently no consensus on its indications, duration or dosage (12).

We present a case of a patient diagnosed with DIP and outline his diagnostic and therapeutic journey with the aim of expanding the case pool of patients with DIP and providing clinical data for the diagnosis of DIP.

## Case report

A 73-year-old male patient, who worked as a farmer in Weifang, China, was admitted to the Department of Respiratory and Critical Care Medicine of Weifang Second People's Hospital (Weifang, China) in June 2019 due to chest tightness, shortness of breath and intermittent fever for 6 months. At 6 months before admission, the patient had developed chest tightness and shortness of breath, which aggravated after physical activity. This was accompanied with intermittent fever at 37.5°C, without any obvious regularity. Further medical examination results on admission are provided in Table I; the results showed that the patient's respiratory rate was slightly higher than the reference value, indicating the need for further evaluation of pulmonary ventilation. The patient had no chest pain or hemoptysis, no nocturnal paroxysmal dyspnea, cough or pink foam-like sputum. After oral treatment with Chai Hu oral liquid (10 ml twice a day), the patient's symptoms of chest tightness and shortness of breath were still not relieved, so she came to our hospital. The patient had a history of smoking for 60 years (20 cigarettes per day) and had quit smoking for 6 months. The patient had no family history of hereditary diseases.

The results of the blood gas analysis and the reference ranges are shown in Table II and values were as follows: Oxygen partial pressure, 81 mmHg; carbon dioxide partial pressure, 34 mmHg; pH, 7.44; the results were not abnormal. Furthermore, the leukocyte count was  $9.82 \times 10^9/l$ , the lymphocyte count was  $2.62 \times 10^9/l$ , the neutrophil percentage was 65.6%, the blood sedimentation rate was 60 mm/h, hypersensitive C-reactive protein level was 36.20 mg/l, blood glucose

Table I. Medical examination results on admission.

Parameter	Value	Reference range
Body temperature, °C	36.8	36.3-37.2
Heart rate, beats per min	85	60-100
Respiratory rate, breaths per min	22	15-20
Blood pressure, mmHg	130/80	90/60-120/80

Table II. Results of diagnostic tests.

Parameter	Value	Reference range
Blood gas		
Oxygen partial pressure, mmHg	81	80-100
Carbon dioxide partial pressure, mmHg	34	35-45
pH	7.44	7.35-7.45
Blood biochemical analysis		
White blood cell count, $10^9/l$	9.82	3.5-9.5
Lymphocyte count, $10^9/l$	2.62	0.8-4
Neutrophil percentage, %	65.6	50-75
Blood sedimentation, mm/h	60	0-20
Ultrasensitive C-reactive protein, mg/l	36.20	0-10.0
Blood glucose, mmol/l	6.91	3.9-6.1
Calcitonin, ng/ml	0.1	0-0.05
Pathogenetic testing		
Gram-positive cocci	+	-
Influenza A virus	-	-
Influenza B virus	-	-
Cytomegalovirus	-	-
Pulmonary function		
FEV1, l	12.39	>92
FEV1/forced vital capacity, %	73.64	>75
Carbon monoxide diffusing capacity, %	68.2	26.5-36.9
FEV1, forced expiratory volume in 1 sec.		

level was 6.91 mmol/l and calcitonin level was 0.1 ng/ml. The results indicated that the lymphocyte count was higher than the reference range, and it was considered that the patient may have a lung infection. A small number of gram-positive cocci were detected in the patient's sputum smear test, while throat swabs tested negative for influenza A and B viruses and cytomegalovirus. Pulmonary function examination indicated the following: Forced expiratory volume in 1 sec (FEV1), 12.39 l; FEV1/forced vital capacity, 73.64%; and carbon monoxide diffusing capacity (DLCO; actual value/predicted value), 68.2%, which indicated small airway dysfunction and decreased diffusion capacity. Chest CT (Optima CT660; GE HealthCare; slice interval, 5 mm; 120 kV) revealed diffuse

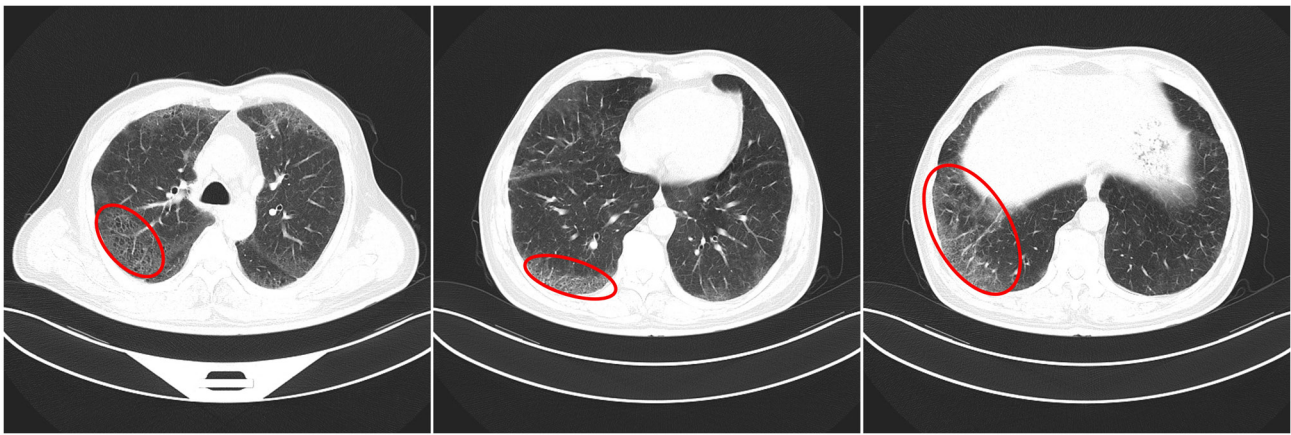


Figure 1. Chest CT indicating multiple ground glass shadows in both lungs and some cysts were found (lesion sites are circled in red; June 2019).

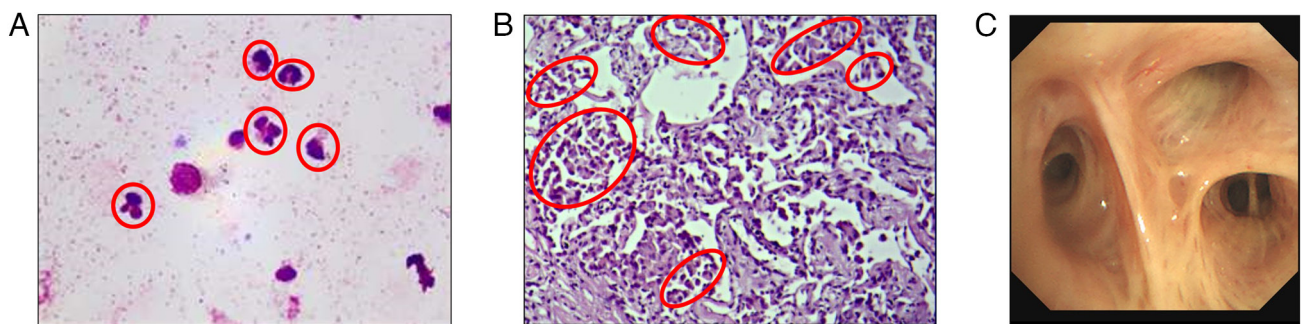


Figure 2. Pathology of transbronchial lung biopsy showing a large number of macrophages in the alveolar cavity and the cytological examination of lavage fluid indicating mainly neutrophils. (A) Bronchoalveolar lavage fluid was tested. The results showed a significantly elevated percentage of neutrophils (circled in red) (Rachel Kiernsa stain; magnification, x1,000; oil microscopy). (B) Histopathological examination showed a large number of macrophages accumulating in the alveolar space (circled in red) (hematoxylin-eosin staining; magnification, x100). (C) Bronchoscopic presentation of the patient.

ground glass shadows in both lungs, with clear margins under the pleura, cystic cavity in some parts and a solid nodule in the outer basal segment of the left lower lobe (Fig. 1).

In conjunction with the patient's medical history, laboratory tests and imaging findings, the diagnosis indicated a noninfectious disease, such as Langerhans histiocytosis, lymphocytic interstitial pneumonia, Birt-Hogg-Dubé syndrome, and DIP. In addition, a panel of possible non-infectious diseases, such as Langerhans histiocytosis, LIP, lung manifestations of BHD syndrome and DIP, were considered. Therefore, bronchoscopy and alveolar lavage fluid (BALF) cell pathogen culture, in addition to transbronchial lung biopsy (TBLB) histopathology, were performed (13).

In June 2019, bronchoscopy revealed bronchial mucosa hypertrophy and hyperemia. TBLB was performed in the upper segment of the right upper lobe bronchus. Cytological and etiological examination were performed using BALF. The BALF was filtered through a 300-mesh nylon filter, acidified with glacial acetic acid, and then subjected to microscopic hand counting of nucleated cells (epithelial cells were excluded from the count). The filtered BALF was centrifuged at 800 x g for 7 min. Of the supernatant, 300  $\mu$ l was left to resuspend the cells, 20  $\mu$ l were aspirated and a smear was prepared from this. Staining was performed using Wright-Giemsa Staining (Beso) for 10 min at room temperature and 400-600 non-epithelial nucleated cells were counted under an oil microscope. The

classification results were presented as a percentage (Fig. 2). The sample was negative for pathogens according to standard procedures. Cytological examination showed predominantly neutrophils in the ALF. Lung biopsy samples were examined using HE staining. The fresh specimens were dehydrated with gradient alcohol at room temperature, followed by sequential immersion in xylene at room temperature and paraffin at 65°C for embedding. Afterward, the pathological tissues were sliced into 5- $\mu$ m thin sections and then consecutively immersed in xylene, anhydrous ethanol, 95% ethanol, 80% ethanol and running water at room temperature. They were stained with hematoxylin for 5 min and eosin for 1 min, dehydrated using a gradient of alcohol, and finally sealed with neutral resin. The pathological results showed that the alveolar septum was slightly wider, where small quantities of lymphocytes and neutrophils had infiltrated the interstitial tissue, with macrophages accumulating in the alveolar cavity.

According to previous reports on DIP, patients with this disease tended to present with restrictive ventilatory dysfunction, where imaging typically shows bilateral diffuse ground-glass shadows with large numbers of macrophages detectable in the BALF (14). In the present report, the patient exhibited significant pulmonary restriction and reduced diffusion capacity upon admission. Imaging tests showed diffuse ground glass shadows in both lungs with subpleural foci and clear margins. Biopsy of the lung tissue revealed slightly

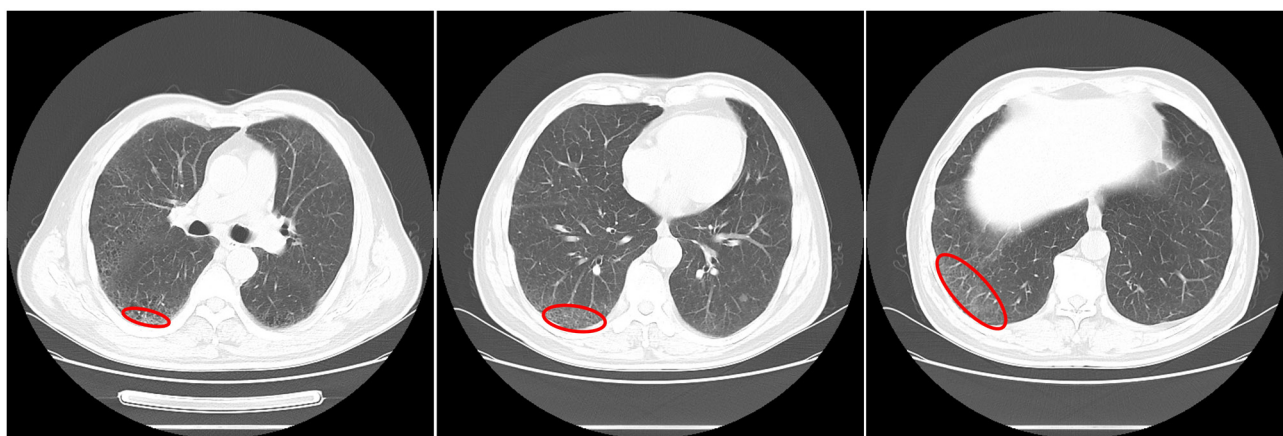


Figure 3. Chest CT in July 2019 indicating that the ground glass opacity was further absorbed and decreased (lesion sites are circled in red, 2019 July 30).

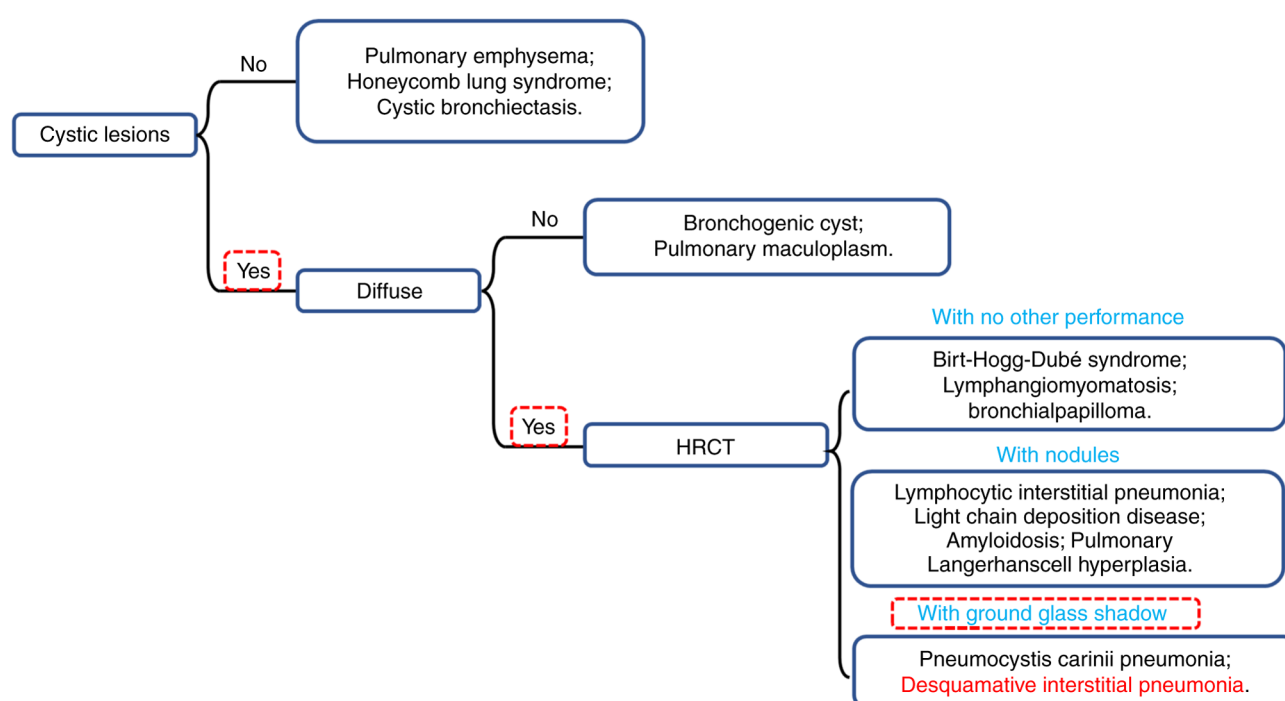


Figure 4. Diagnostic process of desquamative interstitial pneumonia disease. HRCT, high-resolution CT.

widened alveolar septa, interstitial infiltration of a few lymphocytes and neutrophils and multiple macrophage aggregates in the alveolar lumen, all of which were shown according to the results of BALF and TBLB pathology. These histological features are characteristic of DIP. The patient was instructed to quit smoking and inhale budesonide and formoterol fumarate powder for inhalation (15,16) (160  $\mu$ g/bid; AstraZeneca) for 38 days, during which time the patient remained abstinent from smoking. Chest CT scan was reperformed in July 2019, where the ground glass shadow was further reduced (Fig. 3). Lung function examination suggested that the FEV1 was 12.64 l, the DLCO (actual value/predicted value) was 76.2%, the FEV1/FVC was 71.74% and lung function had improved. In August 2019, the patient had no fever, and the cough and shortness of breath had improved significantly. The patient was able to breathe normally and no longer felt any chest tightness. The patient was also instructed to gradually reduce the use of

the drug to prevent a rebound phenomenon. The patient was followed up by telephone at 1, 3 and 6 months after discharge. The patient discontinued medication and successfully maintained smoking cessation within 1 month after discharge. There was no recurrence of the disease.

## Discussion

DIP is a rare group of lung diseases of unknown etiology and belongs to the category of interstitial pneumonia that was first reported by Liebow and Billingsley (6) in 1965. A large number of cells, which was considered to be epithelial cells at the time (they were later shown to be macrophages), were initially observed in the alveolar lumen of patients with DIP. This feature was at first proposed to be due to pulmonary epithelial cell desquamation, giving rise to its name (6). In non-smoking patients, possible causes of DIP include hepatitis

Table III. Diagnostic features and treatment options for related diseases.

Disease	Pathogenesis	Main symptoms/features	Accompanying symptoms	Treatment options	(Refs.)
<i>Yersinia</i> pneumonia	<i>Yersinia enterocolitica</i> infection	Swollen and painful lymph nodes, highly contagious	Sepsis without pustules, hyperthermia, bleeding tendency	Third generation cephalosporins	(34)
<i>Staphylococcal</i> pneumonia	<i>Staphylococcus</i> infection	Massive hemoptysis, rapid accumulation of pleural effusion, acute respiratory distress and leukopenia	Periphereal circulatory collapse and corresponding organ damage	Cefazolin, Zocillin or Ceftazolin	(35)
Pulmonary Langerhans cell histiocytosis	Closely related to tobacco exposure	Eosinophilic granuloma with Langerhans cell infiltration and destruction of the distal airway	Extrapulmonary lysis lesions, skin lesions or central nervous system involvement and skeletal system	Smoking cessation and treatment based on clarabine or cytarabine	(36,37)
Lymphangioliomyomatosis	Cause of disease not known	Dyspnea, cough, chest pain, and hemoptysis; spontaneous pneumothorax is common.	Axial lymph node enlargement in the pelvis, abdomen and chest, smooth muscle tumors in the abdominal lymphatics	Macrolide immunosuppressants	(38,39)
Lymphocytic interstitial pneumonia	Autoimmune and environmental factors are involved	The main respiratory manifestation is dry cough	Bronchospasm and cough	Glucocorticoids, steroids and $\gamma$ -globulin therapy	(1,40)
Birt-Hogg-Dubé syndrome	Germline mutations in the <i>folliculin</i> gene on chromosome 17p11.2	Intrapulmonary cysts in both lungs and secondary spontaneous pneumothorax	Multiple, yellowish or white, prominent flat, round, smooth papules 1-5 mm in diameter on the face, neck and upper trunk	There is no known effective treatment	(41)



C virus or cytomegalovirus infection, chronic mold exposure and inorganic particle accumulation, such as welding, diesel fumes and metalworking (17,18). However, long-term exposure to mycotoxins or dust, in addition to the long-term use of various drugs, such as sirolimus, furantoin and/or illicit drugs, such as marijuana, have also been reported to contribute to the development of DIP. In pediatric patients, the cause is more likely to be familial, especially if there was a history of hereditary interstitial pneumonia (19).

Although DIP is part of the DCLD family, treatment options for individual cases of DCLDs can drastically vary. Therefore, accurate diagnosis of DIP is critical for the treatment of DIP. This case summarizes the features of various pulmonary diseases that are similar to the manifestations of DIP and a flow chart for confirming the diagnosis of DIP was generated, which would facilitate the accurate diagnosis of suspected DIP in future cases (Fig. 4 and Table III). The gold standard for diagnosing DIP is open chest biopsy, but this procedure can pose greater harm to the patient. Therefore, methods such as high-resolution CT and bronchoscopy have become the primary criteria for its differential diagnosis. DIP is characterized by bilateral areas of grossly glassy opacity in the lungs on imaging and pathologically by macrophage infiltration of the alveoli. Currently, the main treatment approach involves counseling patients to stop smoking and using glucocorticoids (20).

The characteristic lesion in patients with DIP, as observed by CT, is a bilateral ground glass shadow in the lungs, occurring mostly in the peripheral and lower lung regions. Examination of the BALF should reveal increased numbers of neutrophils, eosinophils and lymphocytes. However, not all patients with DIP exhibit an increase in all of the aforementioned mature leukocytes. Patients may only exhibit an increase in one or more of these cell types (10,21,22). Previously, an open-chest biopsy was considered the most powerful means of identifying DIP (20,23). On chest radiography, the benign tumor typically appears nodular and is located mostly in the lower lobes, with peripheral lesions of variable sizes. On CT examination, such tumors frequently contain punctate calcifications. A number of retrospective studies have shown that positron emission tomography cannot sufficiently differentiate between inflammation and malignancy, rendering resection to be the only definitive diagnostic method for this type of pathology (24,25). With the advancement of histopathologic and transbronchial biopsy techniques, it is now possible to diagnose DIP effectively while minimizing patient harm compared to open biopsy, open-chest biopsy has been gradually replaced (26). In addition, the TBLB technique used in the present case has markedly reduced the postoperative recovery time of patients, whilst accurately diagnosing their disease (3). The TBLB technique enhances the accuracy of diagnosing DIP, reduces the likelihood of missed or incorrect diagnoses, enables more aggressive and effective treatment and ultimately improves prognosis, the prognosis for diffuse interstitial pneumonia (DIP) is generally favorable, with most patients showing improvement after quitting smoking and receiving corticosteroid therapy. The 10-year survival rate is ~70% and the mortality rate ranges from 6 to 28% (16,27). Similar to the previous cases of DIP, hormonal therapy was chosen as the treatment regimen for the present case. Hormonal therapy is

currently the most commonly used treatment option for DIP and has demonstrated superior clinical benefits both in terms of short-term treatments lasting a few weeks and long-term treatments lasting more than 6 months (3).

Although it has been 58 years since the first case of DIP was reported, further exploration is required regarding the causes of this disease. In a previous review by Hellemons *et al* (28), case reports of DIP between 1965 and 2019 were summarized, which proposed that the most common clinical symptoms of this disease are dyspnea and coughing. In addition, patients will typically exhibit pulmonary function limitation (70%) with reduced diffusion capacity, and majority of patients achieve the alleviation of symptoms after treatment with glucocorticoids (13). In another study by Craig *et al* (29), who followed up 49 patients at Royal Brompton Hospital (London, UK), with DIP, the average survival was found to be 8.8 years for non-smokers and 7 years for smokers. Although the presence of hazardous substance-related occupational exposures in the patient population does not allow for a definitive conclusion that smoking significantly reduces patient survival, smoking cessation is generally included in treatment recommendations to prevent further deterioration in patient condition (30). Oral glucocorticoids, such as prednisone, have been the most commonly used treatment option for DIP in several previous case reports (31,32). Typically, hormone administration provides immediate relief of the patient's dyspnea and shows an improvement effect on lung function in the long-term control of DIP (33). In addition, depending on the patient's condition, immunosuppressants and antimicrobials can be supplemented into the treatment regimen to target the different symptoms. For example, allergies or bacterial infections may be present.

In the treatment regimen reported in the present report, the patient was initially advised to abstain from smoking. This step has been demonstrated to be crucial for the improvement of DIP, as evidenced previously (3,13). Considering that the patient was admitted with an elevated respiratory rate and chest tightness and there was a possibility of a gram-positive *Coccobacillus* infection (follow-up tests proved that the patient was not infected with the bacteria), the patient received continuous low-flow oxygen, anti-infective therapy and asthma control therapy during his hospitalization. The patient did not exhibit severe dyspnea or decreased oxygen saturation. After 8 days of treatment, the patient was discharged after his symptoms improved significantly. Considering that the patient was unable to maintain oxygenation or receive nursing care after being discharged, the patient was prescribed treatment with the glucocorticoid aerosol Sinebicort (AstraZeneca).

Certain limitations of the present report remain. The present report only included one case, which prevented some of the characteristics and treatment protocols in the present report from being applied for the wider diagnosis and treatment of all patients with DIP. Furthermore, a follow-up telephone call was made and the patient indicated that there had been no relapse of the disease after discontinuing the medication, but since the patient did not return for a follow-up visit, there was no imaging information available to accurately verify his recovery.

This case demonstrates that combining low-flow oxygen supply with glucocorticoid therapy for treating a patient with DIP, and using asthma-relieving medications for the

patient's apparent chest tightness, may have a more positive impact on the patient's treatment. Although glucocorticoid therapy has become the primary treatment for DIP, there is no consensus on the indications, duration and dosage of hormone use. Since the number of patients with this disease is small and there are not sufficient clinical samples to summarize the diagnostic indicators. At Weifang Second People's Hospital, a number of DIP cases have already been collected, where the treatment regimens and prognosis of the patients are planned to be documented in more detail. The present report intends to raise awareness of the disease to reduce the rate of missed diagnoses and misdiagnoses, promote effective treatment, improve patient compliance, and enhance the prognosis.

### Acknowledgements

Not applicable.

### Funding

The present study was supported by funds from the Science and Technology Development Project of Weifang (grant nos. 2021YX070 and 2022ZJ1059), Scientific Project of Weifang Health Commission (grant no. WFWSJK-2022-220) and the Chinese Federation of Public Health Foundation (grant no. GWLM202043).

### Availability of data and materials

The datasets used and/or analyzed during the current study are available from the corresponding author on reasonable request.

### Authors' contributions

MQ, HZ and YZ were responsible for the conception of this work. HZ was a major contributor in writing the manuscript. GY, BY, SM, YW, HZ and XZ assisted with the data analysis and drafted the discussion part of the manuscript. MQ and YZ confirm the authenticity of all the raw data. All authors have read and approved the final manuscript.

### Ethics approval and consent to participate

Examination images of the patient, including chest CT, bronchoscopy and cytology, were used in this case, and patient information had been withheld, requiring ethical approval. The present report was approved by the ethics committee of Weifang Second People's Hospital (Weifang, China; approval no. RY2022-025-01).

### Patient consent for publication

The patient provided written informed consent for the publication of the manuscript including any identifying images or data.

### Competing interests

The authors declare that they have no competing interests.

### References

1. Panchabhai TS, Farver C and Highland KB: Lymphocytic interstitial pneumonia. *Clin Chest Med* 37: 463-474, 2016.
2. Radzikowska E: Update on pulmonary Langerhans cell histiocytosis. *Front Med (Lausanne)* 7: 582581, 2021.
3. Diken ÖE, Şengül A, Beyan AC, Ayten Ö, Mutlu LC and Okutan O: Desquamative interstitial pneumonia: Risk factors, laboratory and bronchoalveolar lavage findings, radiological and histopathological examination, clinical features, treatment and prognosis. *Exp Ther Med* 17: 587-595, 2019.
4. Obaidat B, Yazdani D, Wikenheiser-Brokamp KA and Gupta N: Diffuse cystic lung diseases. *Respir Care* 65: 111-126, 2020.
5. Ryu JH, Tian X, Baqir M and Xu K: Diffuse cystic lung diseases. *Front Med* 7: 316-327, 2013.
6. Liebow AA, Steer A and Billingsley JG: Desquamative interstitial pneumonia. *Am J Med* 39: 369-404, 1965.
7. Godbert B, Wissler MP and Vignaud JM: Desquamative interstitial pneumonia: An analytic review with an emphasis on aetiology. *Eur Respir Rev* 22: 117-123, 2013.
8. Hino T, Lee KS, Yoo H, Han J, Franks TJ and Hatabu H: Interstitial lung abnormality (ILA) and nonspecific interstitial pneumonia (NSIP). *Eur J Radiol Open* 8: 100336, 2021.
9. Wells AU, Nicholson AG and Hansell DM: Challenges in pulmonary fibrosis. 4: Smoking-induced diffuse interstitial lung diseases. *Thorax* 62: 904-910, 2007.
10. Blin T, De Muret A, Teulier M, Ferreira M, Vincent M, Catonin M, Legras A, Diot P and Marchand-Adam S: Desquamative interstitial pneumonia induced by metal exposure. A case report and literature review. *Sarcoidosis Vasc Diffuse Lung Dis* 37: 79-84, 2020.
11. Serrano Gotarredona MP, Navarro Herrero S, Gómez Izquierdo L and Rodríguez Portal JA: Smoking-related interstitial lung disease. *Radiologia (Engl Ed)* 64 (Suppl 3): S277-S289, 2022.
12. Moreno García MJ, López-Herce Cid J, Rodríguez Sánchez C, Alvarado Ortega F, Carrasco S and Ruza Tarrío F: Desquamative interstitial pneumonia. *An Esp Pediatr* 23: 431-437, 1985.
13. Medenica M and Medenica M: Desquamative interstitial pneumonia with clinical, radiological and histologic correlation. *Radiol Case Rep* 14: 505-509, 2019.
14. Yamakawa H, Suido Y, Sadoyama S, Yamanaka Y, Ikeda S, Kitamura H, Baba T, Okudela K, Takemura T and Ogura T: Desquamative interstitial pneumonia complicated with IgG4-related lung disease. *Intern Med* 56: 1553-1556, 2017.
15. Margaritopoulos GA, Harari S, Caminati A and Antoniou KM: Smoking-related idiopathic interstitial pneumonia: A review. *Respirology* 21: 57-64, 2016.
16. Hagmeyer L and Randerath W: Smoking-related interstitial lung disease. *Dtsch Arztebl Int* 112: 43-50, 2015.
17. Loughheed MD, Roos JO, Waddell WR and Munt PW: Desquamative interstitial pneumonitis and diffuse alveolar damage in textile workers. Potential role of mycotoxins. *Chest* 108: 1196-1200, 1995.
18. Nemery B: Metal toxicity and the respiratory tract. *Eur Respir J* 3: 202-219, 1990.
19. Cottin V: Desquamative interstitial pneumonia: Still orphan and not always benign. *Eur Respir Rev* 29: 200183, 2020.
20. Lovrenski A, Eri Ž, Tegeltija D, Kašiković-Lečić S and Panjković M: Desquamative interstitial pneumonia: A case report. *Srp Arh Celok Lek* 142: 602-606, 2014.
21. Ishimoto H, Sakamoto N, Ozasa M, Tsutsui S, Hara A, Kido T, Yamaguchi H, Yamamoto K, Obase Y, Ishimatsu Y and Mukae H: Idiopathic desquamative interstitial pneumonia diagnosed using transbronchial lung cryobiopsy: A case report. *Respir Med Case Rep* 34: 101523, 2021.
22. Sousa V and Carvalho L: DIP (desquamative interstitial pneumonia): As a tobacco-associated disease-case report. *Rev Port Pneumol* 10: 431-435, 2004 (In Portuguese).
23. Miyaoka M, Hatanaka K, Iwazaki M and Nakamura N: Pulmonary adenocarcinoma mimicking desquamative interstitial pneumonia: Report of 2 cases with genetic analysis. *Int J Surg Pathol* 26: 655-659, 2018.
24. Neacșu F, Vârban AȘ, Simion G, Șurghie R, Pătrașcu OM, Sajin M, Dumitru M and Vrînceanu D: Lung cancer mimickers-a case series of seven patients and review of the literature. *Rom J Morphol Embryol* 62: 697-704, 2021.
25. Furuya K, Yasumori K, Takeo S, Sakino I, Uesugi N, Momosaki S and Muranaka T: Lung CT: Part 1, mimickers of lung cancer-spectrum of CT findings with pathologic correlation. *AJR Am J Roentgenol* 199: W454-W463, 2012.

26. Batra K and Adams TN: Imaging features of idiopathic interstitial lung diseases. *J Thorac Imaging* 38 (Suppl 1): S19-S29, 2023.
27. American Thoracic Society; European Respiratory Society: American thoracic society/European respiratory society international multidisciplinary consensus classification of the idiopathic interstitial pneumonias. This joint statement of the American thoracic society (ATS), and the European respiratory society (ERS) was adopted by the ATS board of directors, June 2001 and by the ERS executive committee, June 2001. *Am J Respir Crit Care Med* 165: 277-304, 2002.
28. Hellemans ME, Moor CC, von der Thüsen J, Rossius M, Odink A, Thorgersten LH, Verschakelen J, Wuyts W, Wijsenbeek MS and Bendstrup E: Desquamative interstitial pneumonia: A systematic review of its features and outcomes. *Eur Respir Rev* 29: 190181, 2020.
29. Craig PJ, Wells AU, Doffman S, Rassl D, Colby TV, Hansell DM, Du Bois RM and Nicholson AG: Desquamative interstitial pneumonia, respiratory bronchiolitis and their relationship to smoking. *Histopathology* 45: 275-282, 2004.
30. Katzenstein AL, Mukhopadhyay S, Zanardi C and Dexter E: Clinically occult interstitial fibrosis in smokers: Classification and significance of a surprisingly common finding in lobectomy specimens. *Hum Pathol* 41: 316-325, 2010.
31. Ryu JH, Colby TV, Hartman TE and Vassallo R: Smoking-related interstitial lung diseases: A concise review. *Eur Respir J* 17: 122-132, 2001.
32. Vassallo R: Diffuse lung diseases in cigarette smokers. *Semin Respir Crit Care Med* 33: 533-542, 2012.
33. Deutsch GH, Young LR, Deterding RR, Fan LL, Dell SD, Bean JA, Brody AS, Noguee LM, Trapnell BC, Langston C, *et al*: Diffuse lung disease in young children: Application of a novel classification scheme. *Am J Respir Crit Care Med* 176: 1120-1128, 2007.
34. Jarrot PA, Mahmoudi R, Novella JL and Manckoundia P: Pneumonia due to *Yersinia enterocolitica*. *Med Mal Infect* 43: 38-39, 2013 (In French).
35. He H and Wunderink RG: *Staphylococcus aureus* pneumonia in the community. *Semin Respir Crit Care Med* 41: 470-479, 2020.
36. Radzikowska E: Pulmonary Langerhans' cell histiocytosis in adults. *Adv Respir Med* 85: 277-289, 2017.
37. Shaw B, Borchers M, Zander D and Gupta N: Pulmonary Langerhans cell histiocytosis. *Semin Respir Crit Care Med* 41: 269-279, 2020.
38. Xu KF, Xu W, Liu S, Yu J, Tian X, Yang Y, Wang ST, Zhang W, Feng R and Zhang T: Lymphangioleiomyomatosis. *Semin Respir Crit Care Med* 41: 256-268, 2020.
39. McCarthy C, Gupta N, Johnson SR, Yu JJ and McCormack FX: Lymphangioleiomyomatosis: Pathogenesis, clinical features, diagnosis, and management. *Lancet Respir Med* 9: 1313-1327, 2021.
40. Pitt J: Lymphocytic interstitial pneumonia. *Pediatr Clin North Am* 38: 89-95, 1991.
41. Daccord C, Good JM, Morren MA, Bonny O, Hohl D and Lazor R: Birt-Hogg-Dubé syndrome. *Eur Respir Rev* 29: 200042, 2020.



Copyright © 2024 Zhang et al. This work is licensed under a Creative Commons Attribution-NonCommercial-NoDerivatives 4.0 International (CC BY-NC-ND 4.0) License.